ECCT

Electro-Capacitive Cancer Therapy

Low intensity low frequency electro-static wave for inhibiting cancer cells growth

Care Clinic
Cancer Research

C-TECH LABS
EDWAR TECHNOLOGY

edwar
healthcare

What Is ECCT?

ECCT (Electro-Capacitive Cancer Therapy) is a method for treating cancer using low intensity and low frequency source (frequency <100KHz and intensity of <30Vpp) of electro-static wave that generates electric polarization in near field region confined by a number of capacitive electrodes embedded in apparels to wear daily by the patients. The technology is invented for the first time by Dr. Warsito P. Taruno and the team in CTech Labs Edwar Technology Company (IDN Patent REG P00201200092, 2012)

Figure 1 ECCT equipment comprises apparel and oscillator.

Principles of ECCT

One of the most prominent characteristics of cancer cell is its uncontrolled cell division. The cell division is linked closely with nano-scale biomolecular activity governed by periodic structural formation and destruction of micro-tubule polymers. The micro-tubule polymers are constructed from micro-tubulin dimers which are highly electrically polarized, thus are sensitive to external electric field. The ECCT is basically the technique to generate such electric field from non-contact capacitive electrodes placed surrounding the location of the tumor with right frequency and intensity to interfere the process of cell division and eventually destroy the cancer cells. With its low frequency and low intensity, ECCT is essentially safe, relatively no side effects and no harm to normal cells.

ECCT Equipments

Principally, the ECCT consists of two parts: the apparel as a support of the capacitive electrodes and oscillator to generate electric wave with certain intensity, waveform and frequency. The ECCT specification for treating cancer is determined by the coverage of the apparel, the frequency, the intensity and waveform of the oscillator, and the time of usage of the equipment that correlate to time exposure of the cancer to electrostatic wave. For complete removal of the cancer, the apparel design is essential in the treatment method, and must be customized according to the tumor position and its staging. In principle, the coverage of the apparel is divided into two types: global coverage for metastasize prevention and local customized coverage for total destruction of the primary tumor. The frequency, intensity and waveform of the oscillator, and the time of usage are determined based on the grade of malignancy of the cancer, the pathology anatomy and the electric properties of the cancer cells. In general, the higher the level of the staging and the higher the degree of the malignancy the more responsive of the cancer to the electric wave and thus the less time needed for exposure as the body has limited capacity to absorb and dissolve the resulted dead cells.

Process and Progress of Cancer Treatment with ECCT

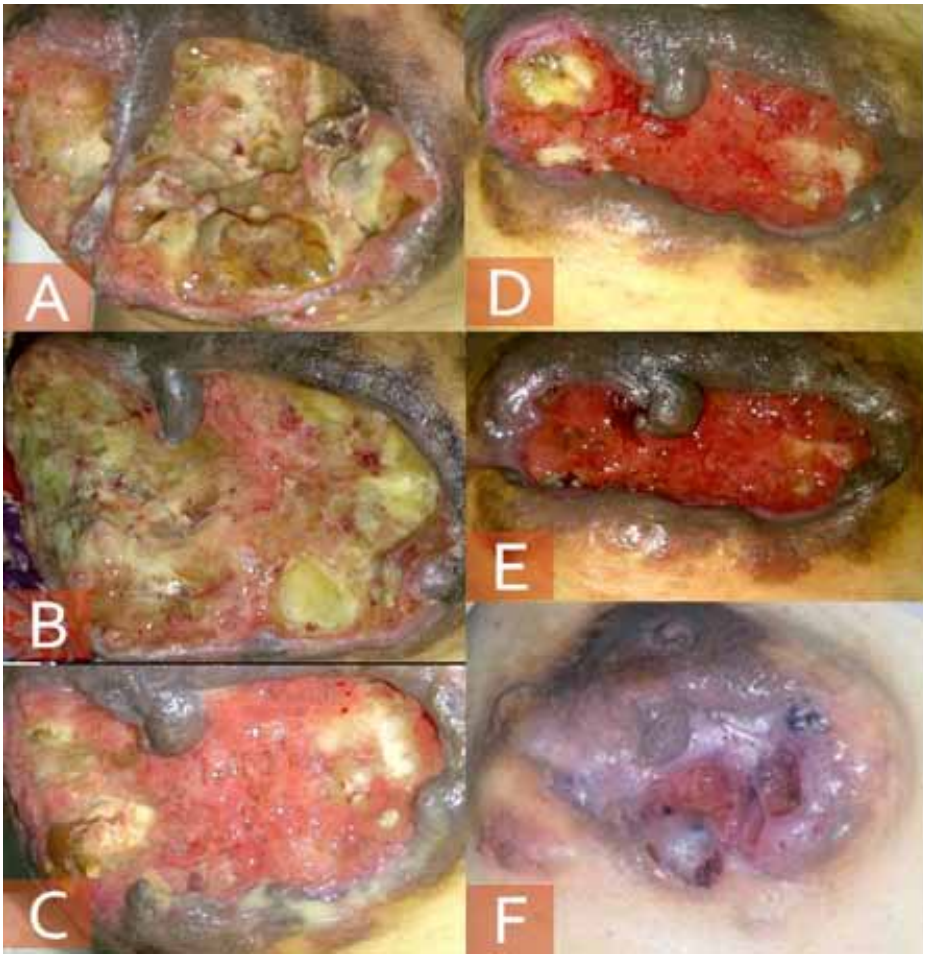

Figure 2 "Melting" cancer cells and regenerating normal cells with ECCT:
A. Initial treatment,
B. 2 months of treatment,
C. 3 months of treatment,
D. 4 months of treatment,
E. 5 months of treatment,
F. 2 years of treatment.

Figure 2 shows the macroscopic process of "melting" cancer cells and regenerating normal cells during the treatment of already open wounded breast cancer. The figure shows that the destruction of cancer cells occur in very short time of within a month, while the regeneration of the normal cells depends on the total removal or absorption of the dead cells and could take years if conducted naturally.

Figure 3 shows two cases of images of the breasts taken by mammography and electrical property imaging using ECVT (Electrical Capacitance Volume Tomography, Taruno et al., 2014) during ECCT treatment. The mammograms on the left shows disappearing small axillary nodules after 6 months of ECCT treatment and dissolving relatively big size (>2 cm in diameter) primary nodule on the breast, while the photograph (left) shows darkened skin as a result of the discharged dead cells. The right photograph shows that the relatively big lump eventually disappear after 2 years of treatment with complete discharge of the dead cells. The ECVT images shows gradual decreases in the electrical properties of the tumors in both cases with the treatment.

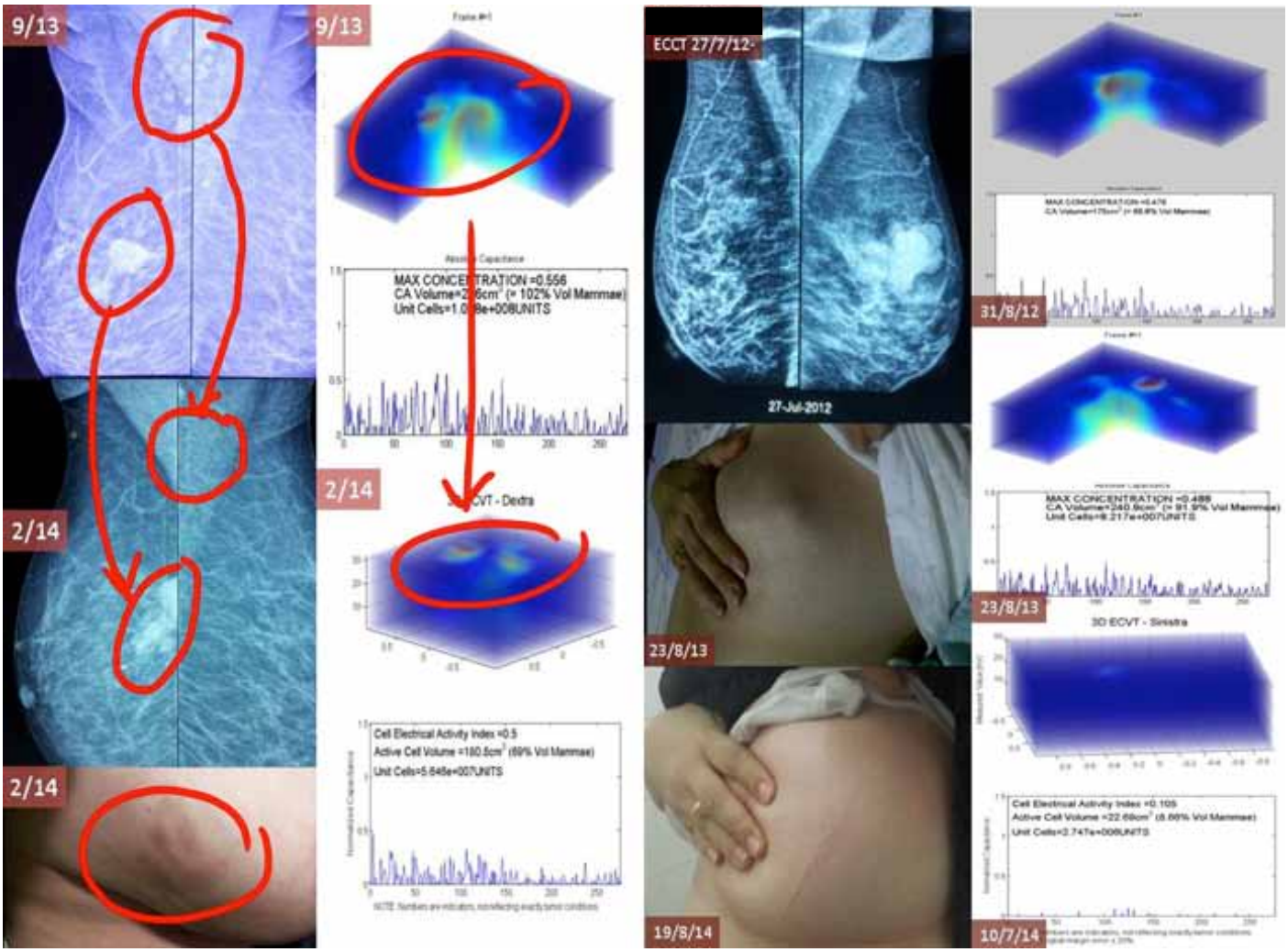

Figure 3 Mammogram and photograph of breast cancers during the ECCT treatment along with the image of electrical properties taken by ECVT.

Why are healthy cells unaffected by ECCT?

The electric properties in cancer cells are different from the healthy ones. Cancer cells have relatively higher electric properties (conductivity and permittivity) as compared to normal cells. Consequently, cancer cells are relatively more responsive to external electric fields than normal cells. The response of cancer cells to external electric field is more salient and destructive during the process of cell division due to the high electric tension generated by micro-tubule activity during the mitosis process. The ECCT is set low enough in the intensity and the frequency to relatively only affect the cancer cells during mitosis.

How to remove dead cancer cells?

A proper ECCT exposure to the designated location of tumors can destroy and break down the cancer cells in relatively short times in the range of few days to few weeks. If designed and used properly, ECCT can exterminate a cancer lump of few centimeter in size within weeks. However some issues may arise to the dead cancer cells if accumulated beyond the capability of the body to absorb and excrete to outside the body in the form of body excretions. The dead cancer cells contain 70% water, 20% protein, and the rest of gas. If the metabolism of the patient is normal, the dead cells can usually be easily absorbed by the blood and discharged through urine, feces, sweat, or phlegm that sometimes comes out with extremely bad odor as a result from decomposed proteins. The effectiveness of the treatment to completely kill the cancer cells will depend on the ability of the body to absorb and resolve all the dead cells as the dead cells, if accumulated, could cause depolarization of the electric field and prevent further process of treatment. Surgery is, therefore, mostly recommended to remove completely and safely the dead cells.

For the case of metastasized cancers, the effectiveness of the treatment depends on the sizes of the metastasized lumps, but not the degree of the spread. Small lumps or nodules regardless of the extension of the distribution in the body is relatively easy to be destroyed by the technique, and the resulted dead cells is easily absorbed and disposed by the body. Therefore the technique is most effective to be used in conjunction with surgery, to clean and prevent metastasize before and after surgery.

Procedure of ECCT Treatment

The procedure of the ECCT treatment comprises three steps: (1) localizing the tumor based on the MRI or CT scan images, (2) designing capacitive electrodes and computing of the electric field distribution inside the treating domain of the tumor, and (3) optimizing the electrode design based on the electric field intensity distribution to attain enough intensity required in the tumor site by considering the possible discharge channel to dispose the dead cells through connected veins linked with the tumor location. Figure 4 shows the illustration of the procedure of the ECCT treatment.

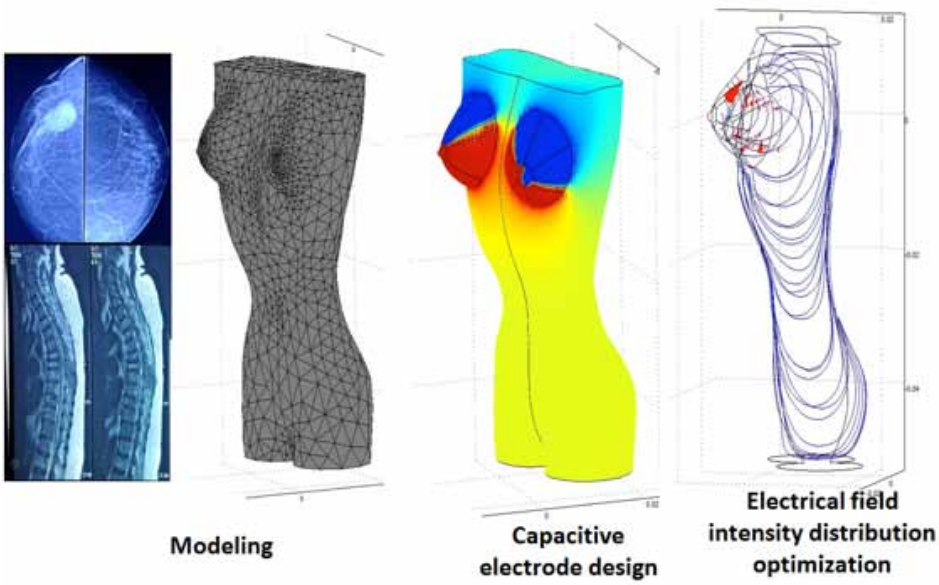

Figure 4 Three steps of ECCT treatment stepwise: (1) Finite element method modeling based on the location of the tumor in MRI or CT scan images, (2) Electrode design and electric field computation, and (3) Optimization of required electric field intensity distribution.

ECCT Treatment for Breast Cancer

Breast cancer is a malignant tumor that starts in the cells of the breast, that can grow into or invade surrounding tissues or spread (metastasize) to distant areas of the body. Effective treatment of breast cancer using the ECCT depends on the ability of the body to absorb and dispose the resulted dead cells to outside the body. The body's ability to absorb the dead cells is more affected by the size of individual lumps or nodules rather than the degree of the metastasize of the cancer.

Optimal Treatment of Breast Cancer with ECCT Based on the Staging

1. Stage 0—1 (Small size nodule of maximum 1—2 cm in diameter, no metastasize):
For breast cancer with small nodules of 1—2cm in diameter, with enough coverage, intensity and usage, usually it takes 4—6 months for the ECCT to completely destroy the cancer cells. The body is usually able to absorb and dissolve the dead cells with no problem.

2. Stage 1—2 (Medium size nodules of 1—2cm in diameter, with no metastasize):
For nodules with sizes of 1—2 cm in diameters, with proper intensity and usage, 1—3 months of ECCT treatment is usually enough to weaken or even completely kill the cancer cells. However, the ability of the body to completely absorb and dissolve the dead cells will depend on the location of the tumor. Sometimes, surgery is needed to remove the weakened or dead cancer cells if the tumor is not linked to main vein system as the discharge channel for the dead cells.

3. Stage 2—3 (Big size of nodules of 2—5cm in diameter, with lymp nodes metastasize, no open wound):
For big sizes of nodules with lymph nodes metastasizes on axillary, mediastinal and supraclavicular nodes and no yet open wound, with proper specification of ECCT treatment, 1—3 months of treatment is usually sufficient to weaken the cancer cells and remove metastasized lymph nodules with small sizes (<1cm). However, usually the body has difficulty to absorb and dissolve the resulted dead cells of the cancer of relatively big sizes (>2cm). For this case, surgery with radical mastectomy for total removal of the weakened cancer cells or minimal incision to open up channel to discharge the residue is usually required. After surgery, it is recommended to use again the ECCT equipment to completely remove the possible remaining cancer cells. If surgery is not performed, accumulated dead cancer cells may cause excessive necrotic and inflammation or even open wound. Open wound may ease the discharge of the dead cancer cells, but the process usually take long time (more than 6 months) to completely heal the wound.

4. Stage 3—4 (Big lump size > 5cm in diameter, metastasized to lymph nodes and/or other organs, with/without open wound):
For the case of big lump breast cancer, with lymph node metastasize on axillary, supraclavicular and mediastinal and/or other organs such as lung, liver, bones and brain, with proper coverage to all possible metastasized area, ECCT usage is conducted started with short period of time, e.g. 4X30 minutes per day depending on the condition of the patient. The usage time is increased with the improvement of the clinical condition. After 3-6 months of treatment, small sizes metastasized nodules (<1 cm) on the lymph nodes and/or other organs (lung, liver, bones and brain) can be significantly reduced or even cleaned up. The treatment of the primary tumor can then be done with surgery to totally remove already weakened cancer cells, or be done naturally if there is open wound to discharge the dead cancer cells if surgery is not possible. The process of clean up of small metastasized nodules usually take relatively short time less than 6 months. However, to completely heal the open wound cancers may take longer time depending on the total removal of the dead cells and the process of regeneration of normal cells in the post wounded area.

5. Stage 4+ (Post-surgery, small sizes (<1cm) metastasize on lymph nodes and/or other organs):
For the case of post-surgical breast (mastectomy or lumpectomy), small sizes metastasizes on the lymph nodes and or other organs can be cleaned up with relatively no problem with the ECCT. With proper coverage to all possible metastasized area and ECCT usage of 6—8 hours per day usually it takes 3—6 months to completely clean up the metastasizes.

Routine Monitoring and Consultations

ECCT treatment is highly customized according to the patient's conditions, the cancer staging, the pathology anatomy and its response to electric field. All treatment is done daily at home while conducting daily activities. The present of doctors or medical physic therapist for routine consultation during the process of treatment is essential for effective and safe treatment to achieve complete cure, which is possible with the ECCT even in the late state of cancers.

Routine Checking of Devices

ECCT is used every day and for a long period of time. Thus, it is necessary to keep up a routine checking (once a month) of ECCT equpments to ensure that all the devices work properly.

Figure A.1 Case Study: Female (47 years old), Breast cancer (invasive ductal carcinoma, grade 4) metastasized to bones: After a radical mastectomy on her left breast, this patient had metastasize of the cancer to the bones in almost all over her body (PET-CT 18/09/12). Before ECCT therapy, the patient felt a tremendous pain on the spine and pelvis, and could only lie on the bed for 7 months. After ECCT treatment, the perceived pain gradually diminished, the patient's condition improved significantly, and slowly the patient is able to stand up and walk again. After 7 months of ECCT treatment, the patient recovered to normal. Results of PET-CT (13/3/14) showed no cancer detected and all laboratory indicators including blood, tumor markers, liver and kidney functions were within normal ranges. The patient has totally recovers to normal activities until now (as of June 2015).

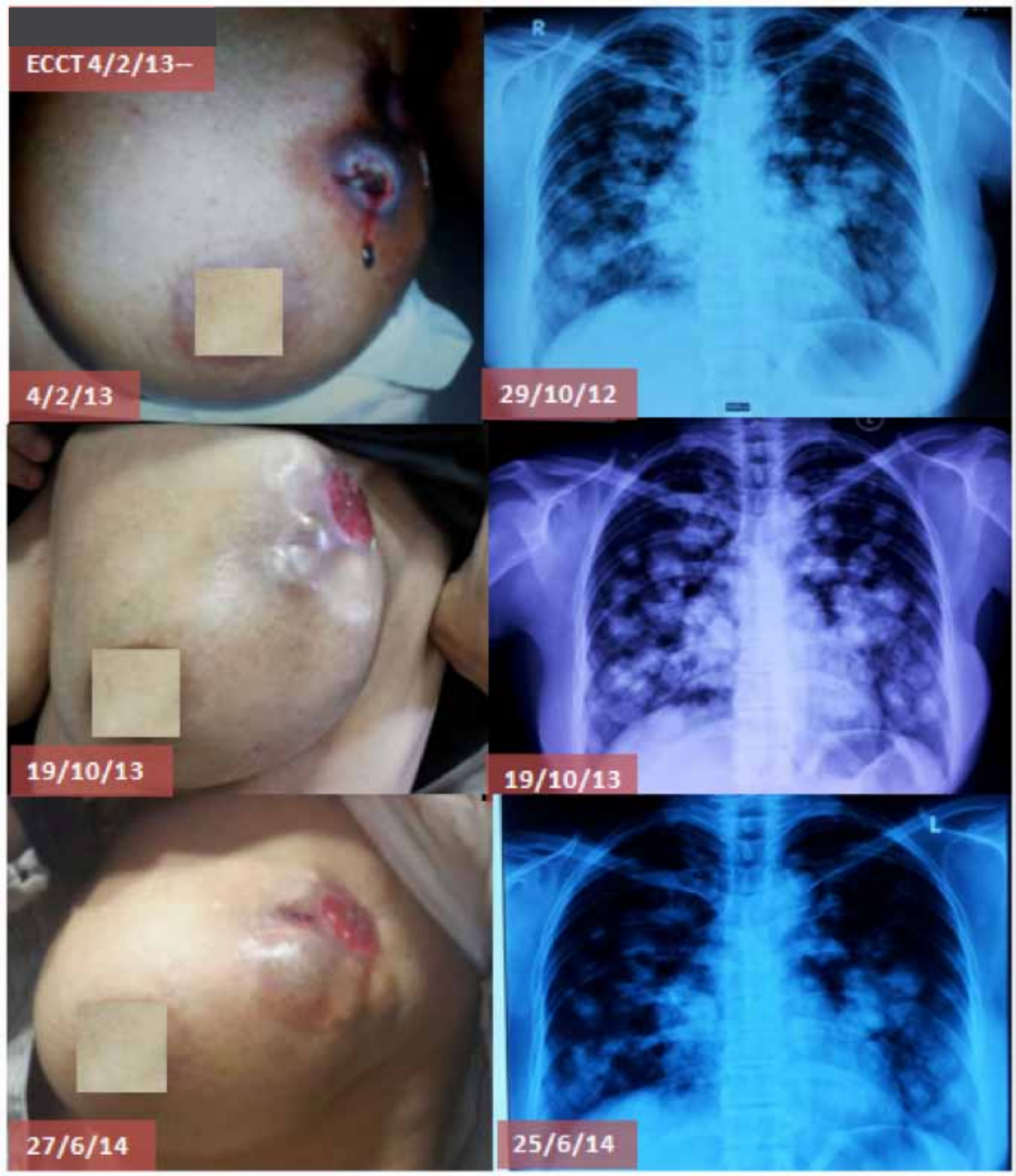

Figure A.2 Case Study: Female (51 years old), breast cancer metastasized to lung: This patients refused to get any conventional medical treatment for her cancer. At initial condition of treatment, there was already an open wound on her left breast (04/02/13) and metastasizes with multiple nodules on both of the right and left lungs. After ECCT treatment for 6 months, the open wound on the breast began to healed and the development of lung nodules restrained (thoracic X-ray photograph (29/10/12) as compared to (19/10/13). After 1 year of treatment, thoracic X-ray photograph showed significantly diminishing nodules on both lungs (thoracic X-ray photograph of 25/06/14), the lump in the breast get softened and shrunk and the wound was healed up. The patient survived until the day the report made (as of June 2015) in good condition.

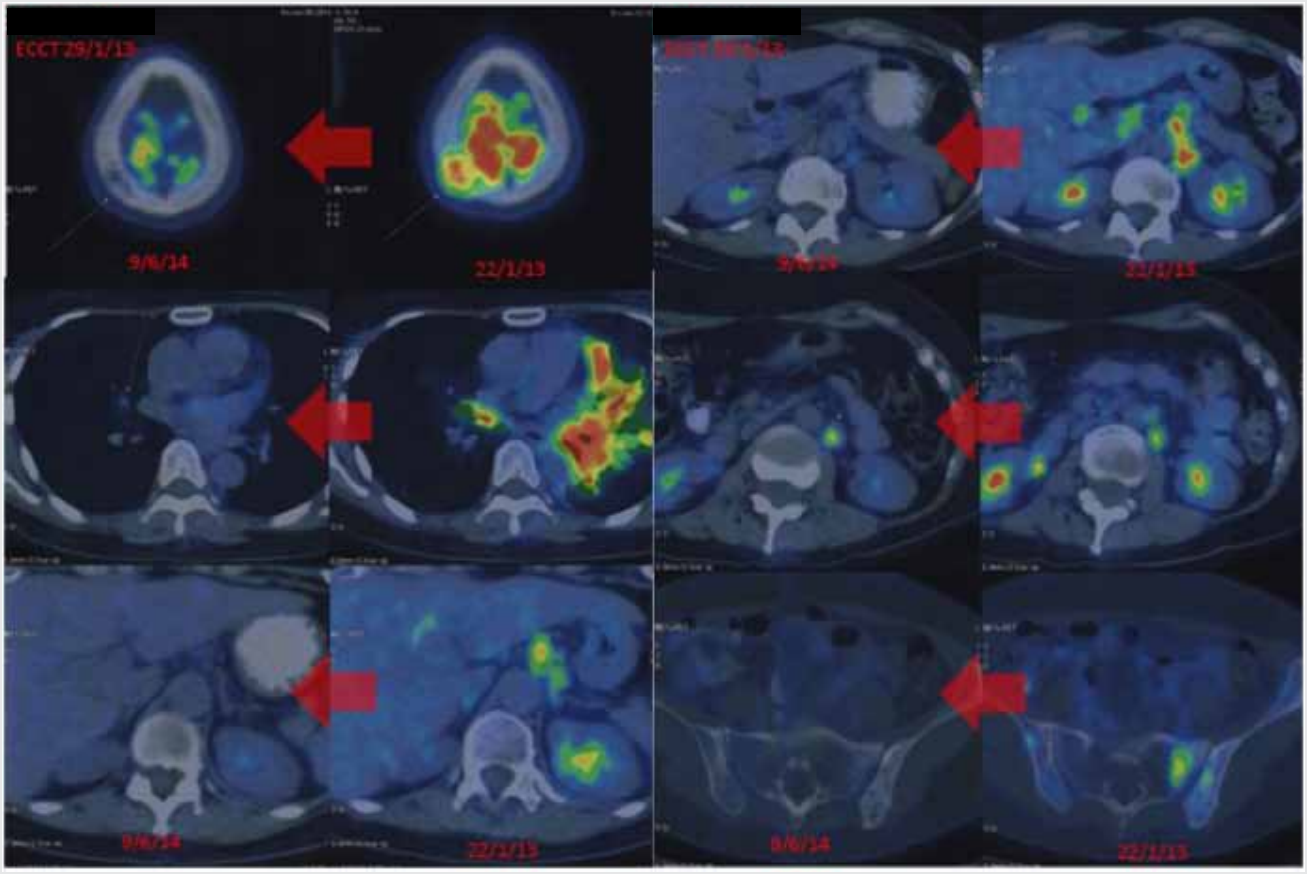

Figure A.3 Case Study: Female (44years old), Breast cancer (grade 4) metastasized to bones, liver, lung, brain and lymph: This patient had conducted radical mastectomy, radiotherapy and chemotherapy, but the cancer has spread to the bones, lungs, lymph and brain (PET CT 22/01/13). The patient's condition before ECCT treatment was weak and feeling intense pain in her pelvis. After ECCT treatment of 1—2 months, the pain on the bone gradually diminished. After one year and half of ECCT treatment, the PET-CT scan (22/01/13) showed the metastasized nodules has almost completely gone. The patient is now in good condition, no essential complaints, with tumor markers in normal levels.

ECCT Treatment for Lung Cancer

According to the data issued by the American Lung Association, there are 54% of lung cancer patients who survive for 5 years in localized lung cancer cases (early stage). However, there are only approximately 15% of those who are diagnosed in the early stage. Most cases are diagnosed in the mid and final stages. This causes significant decrease in the five-year survival rate.

Lung cancer easily spreads to other vital organs such as brain, liver, and bones, which often cause death. Treatment method available today has been far from effective to prevent the metastasize that causes fatalities. Although the primer cancer has been treated accordingly, once the cancer has spread to vital organs, the survival is very poor with prognosis oftenly less that 6 months.

The general procedure of ECCT treatment for lung cancer is shown in Figure 5. The ECCT treatment for lung cancers uses mainly vest types of apparels to cover the whole lung and liver, helmet type of apparel to cover the brain for prevention and customized apparel specifically designed according to the location of the tumor for local coverage. The global coverage is mainly intended for metastasize prevention, while local coverage is designated to completely destroy and kill the primary tumors. The intensity of the oscillator is set according to the pathology anatomy of the lung cancer. The usage time is ranging from 4X30 minutes to 4X2 hours per day based on the staging and the clinical conditions of the patient. The more the degree of the cancer staging and the more the grade of the malignancy the less the time usage of the equipment is required. The total removal of the lung cancer is usually between 6—12 months.

Figure 6 ECCT treatment may be combined with other medical treatments, but usually medication intake that has influence on the immune system will prolong the cure process. The images shows relative longer period of cancer removal with combined oral chemotherapy.

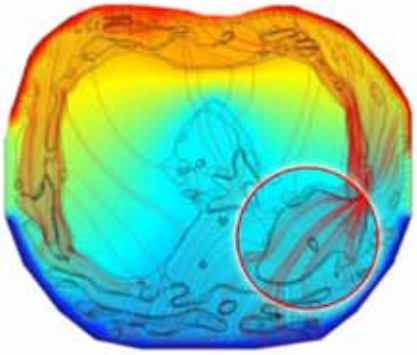

ECCT Electric Field Simulation

Before treatment

After 6 months of treatment

After 2 years of treatment

Figure 5 General procedure of ECCT treatment for lung cancer: the electric field computation and subsequent CT scan images of the lung cancer before and after ECCT treatment. The total time to completely remove the lung cancer ranges from 6 to 12 months if the equipment designed properly.

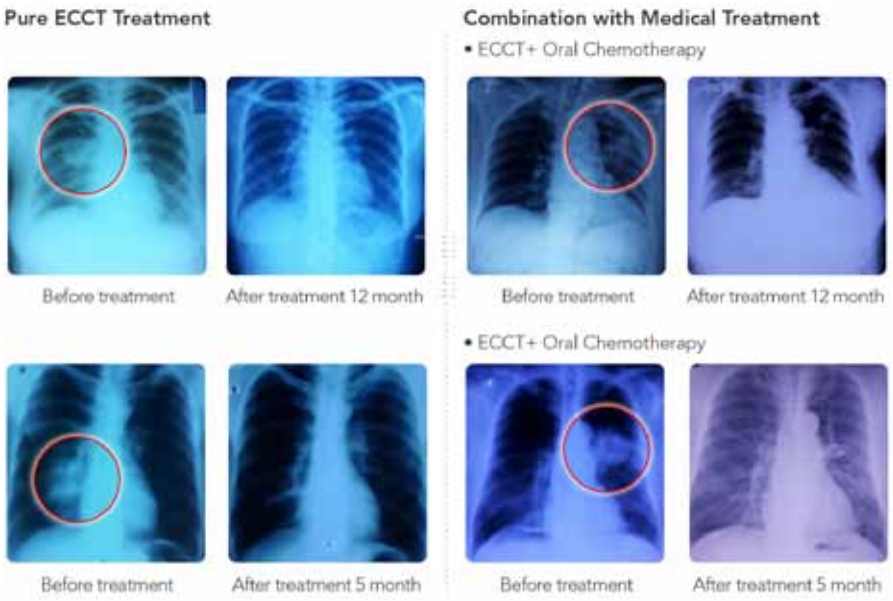

Figure 6 Pure ECCT treatment for lung cancers, as compared to combined ECCT treatment with oral chemotherapy.

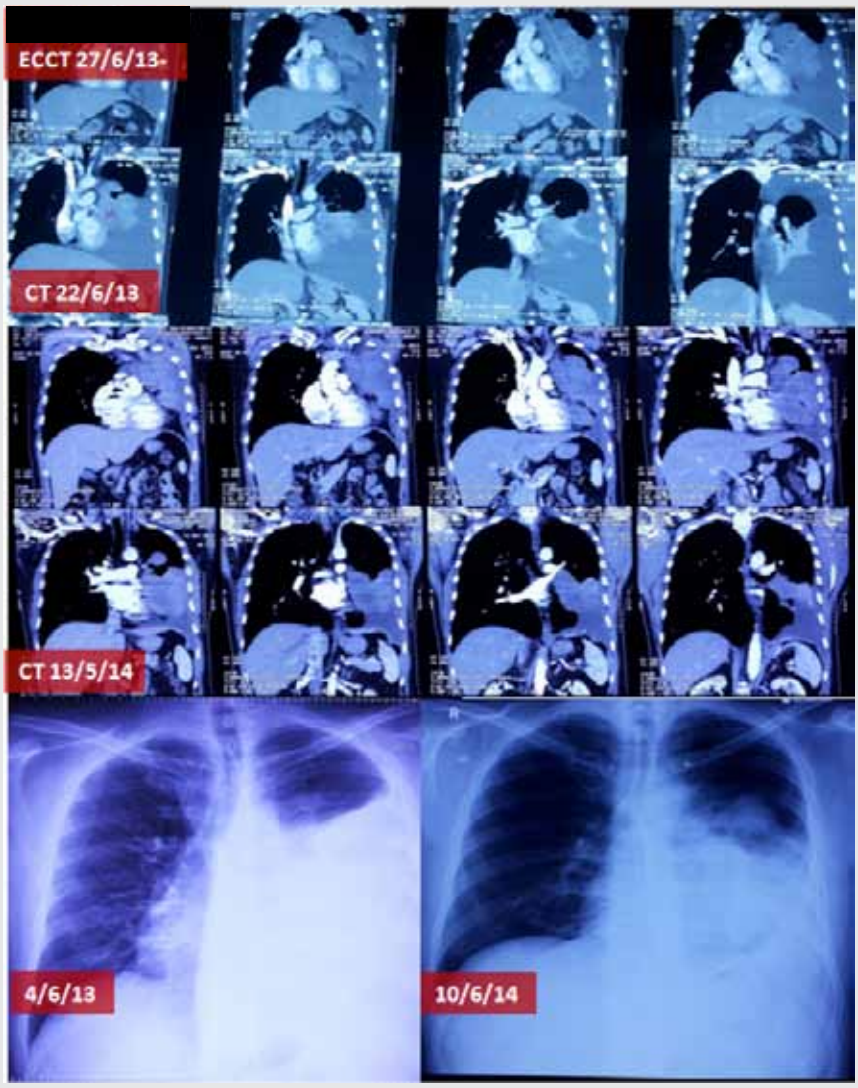

Figure B.1 Case Study: Lung cancer, male (43years old): The patient was diagnosed with a solid mass tumor in the left lung sized 6.8X12.5cm at the hilar; the mass stuck to the heart, the main artery and esophagus, and a massive pleural effusion identified (CT 22/06/13). The initial condition of the patient was complaining with shortness of breath, coughing and chest pain . The presence of pleural effusion required the patient to get drainage of the fluid every 5 days of up to 2000cc. In the early use of ECCT, the shortness of breath, coughing and pleural fluid increased, but the pain quickly reduced. However, after 3 months of treatment, the coughing, shortness of breath and pleural fluid in the lungs began to dissapear, and after 1 year of treatment the size of the mass began to shirnk (CT 13/05/14). The last condition of the patients (as of June, 2015): the shortness of breath almost gone, coughing completely gone. The lung fluid was no more identified, but the solid residue from the settling lung fluids was still remaining.

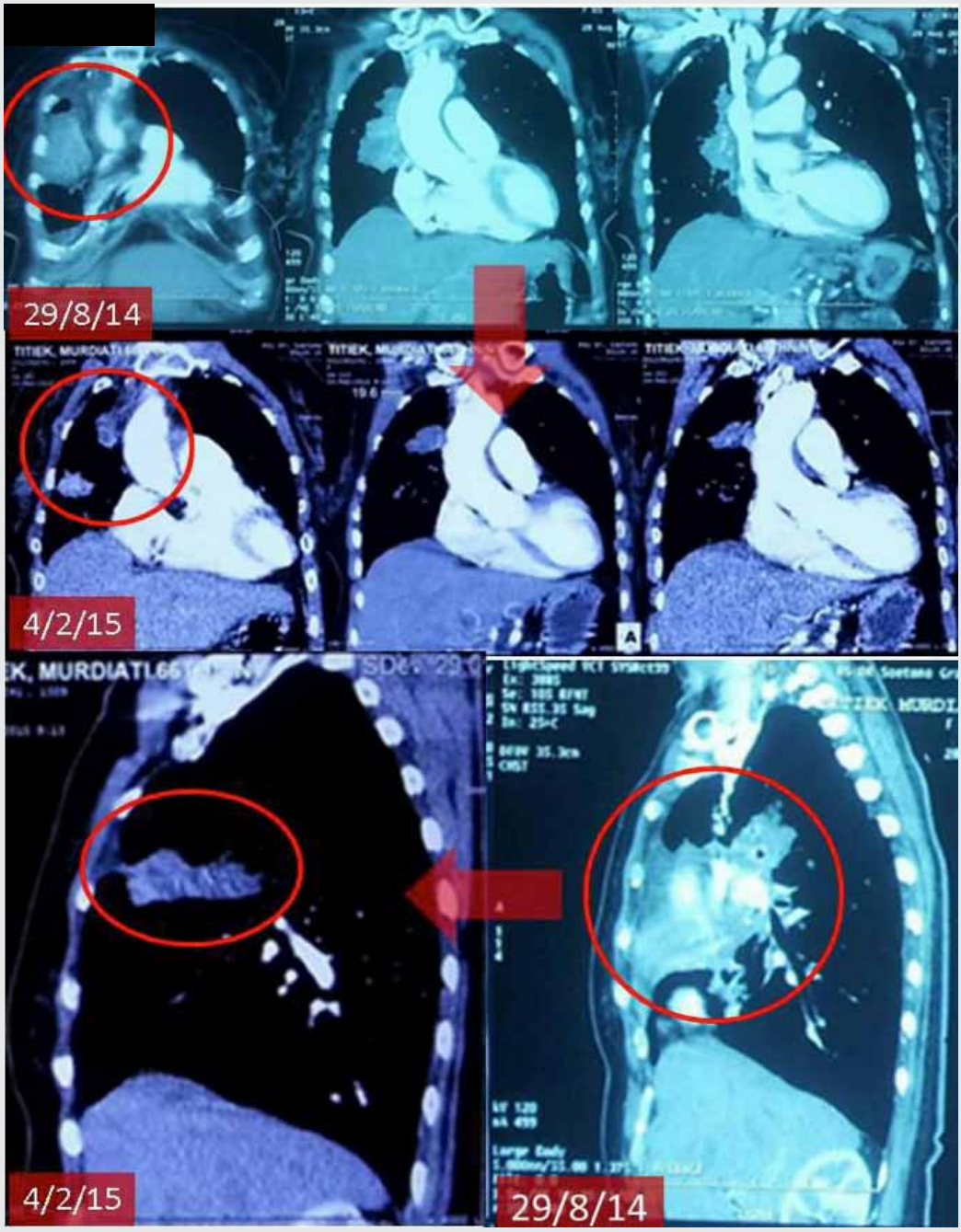

Figure B.2 Case Study : Lung cancer (adenocarcinoma), female (66years old): This Patient was diagnosed with tumor mass in the right lung with multiple nodules in both lungs (CT 29/08/14). The initial condition of the patient was having shortness of breath, coughing, chest pain and drastic weight loss. After a month of ECCT treatment, the shortness of breath, coughing, chest pain have decreased and the appetite has increased significantly. After 6 months of treatment the CT scan (04/02/15) shows significant reduction of the tumor, the patient showed significant improvement clinically, shortness of breath, coughing and chest pain have almost gone, and the patient started getting weight gain.

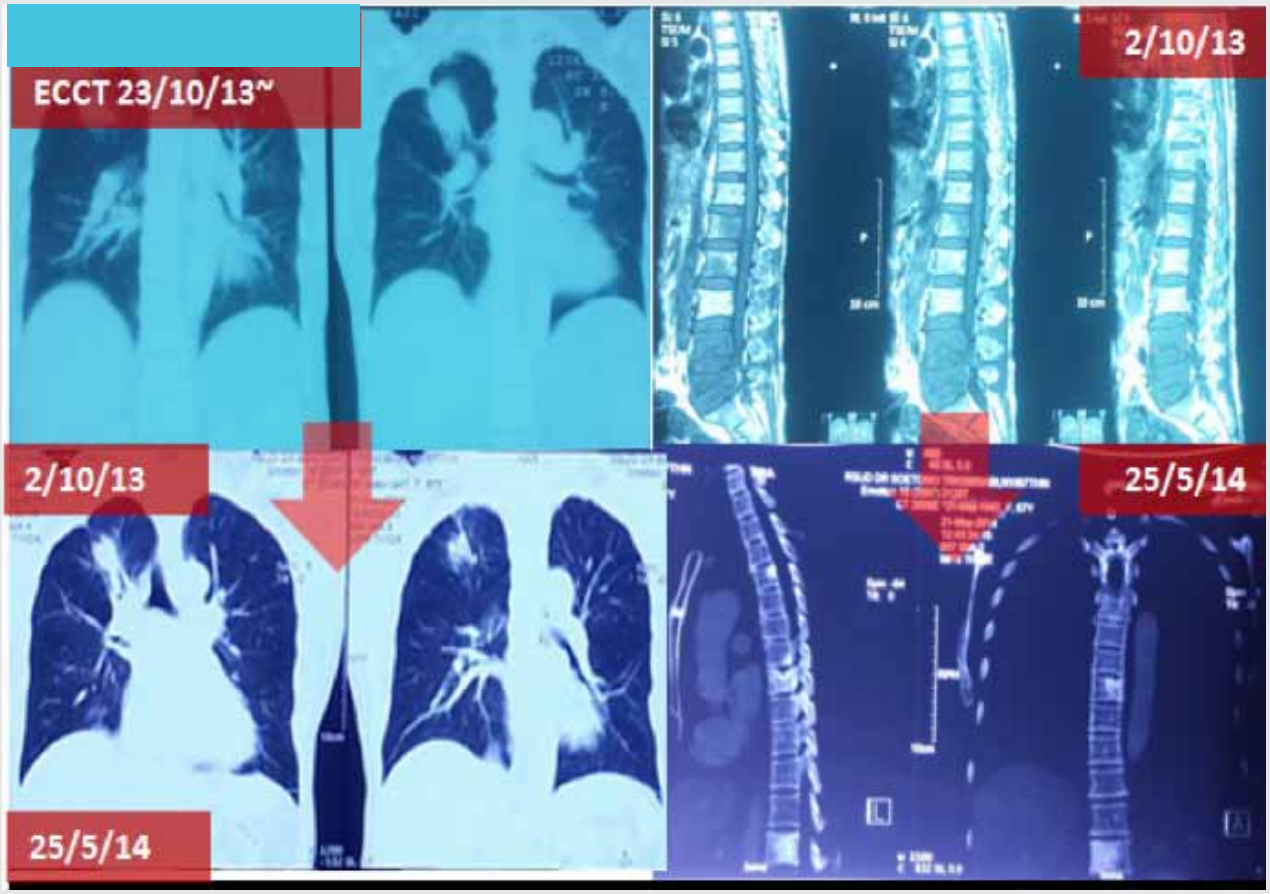

Figure B.3 Case Study: Lung cancer with bone metastasize: The patient was diagnosed with a tumor mass in the right lung at the suprahilar with metastasize on the spine (CT 02/10/13). The patient initially could only lied on the bed, and was very weak and feeling shortness of breath due to pleural effusion in the both lungs. During early use of ECCT, the patient felt severe pain on the bones so the usage was very limited. After one month of treatment, the pain on the bones began to decrease, and after 3 months the general condition began to improve. After 7 months of treatment, the tumor mass on the lung and the bones showed significant reduction, and the patient showed significant clinical improvement, having able to stand up and walk slowly, and the shortness of breath, coughing and lung fluid was completely gone.

ECCT Treatment for Brain Cancer

Glioma accounts for more than 70% of all brain tumors, while astrocytoma and glioblastoma are most common and malignant, histological type of glioma. There is a tendency of a higher glioma incidence in developed countries. However, the prognosis of glioma patients is relatively still poor. The ECCT has been proved as most effective to astrocytoma but less effective to glioblastoma, and less responsive to low grade glioma or other benign brain tumors such as meningioma.

The ECCT treatment to brain cancers usually uses ECCT apparels of helmet type designed to cover the whole brain to prevent cancer spreading to wider area in the brain and customized apparel designed according to the location and the size of the tumor for effective and complete removal of the tumor. The intensity of the oscillator is set depending on the grade of malignancy of the cancer and the location of the tumor by considering possible excessive reaction to the nerve caused by disrupted cancer cells with the ECCT. The usage time for brain cancer treatment is set started with very short time, e.g. 4X15 minutes per day, and increased gradually with the improvement of the clinical conditions of the patient.

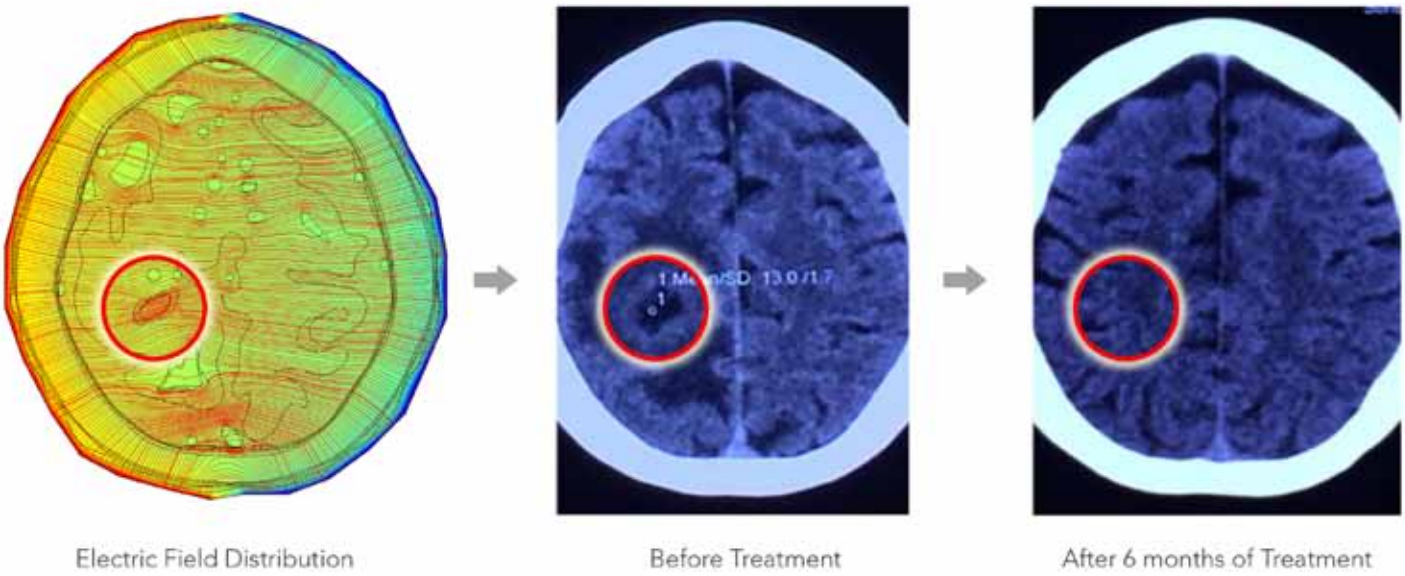

Figure 7 General procedure of ECCT treatment for brain cancer: the electric field computation and subsequent CT scan images of the brain cancer before and after ECCT treatment.

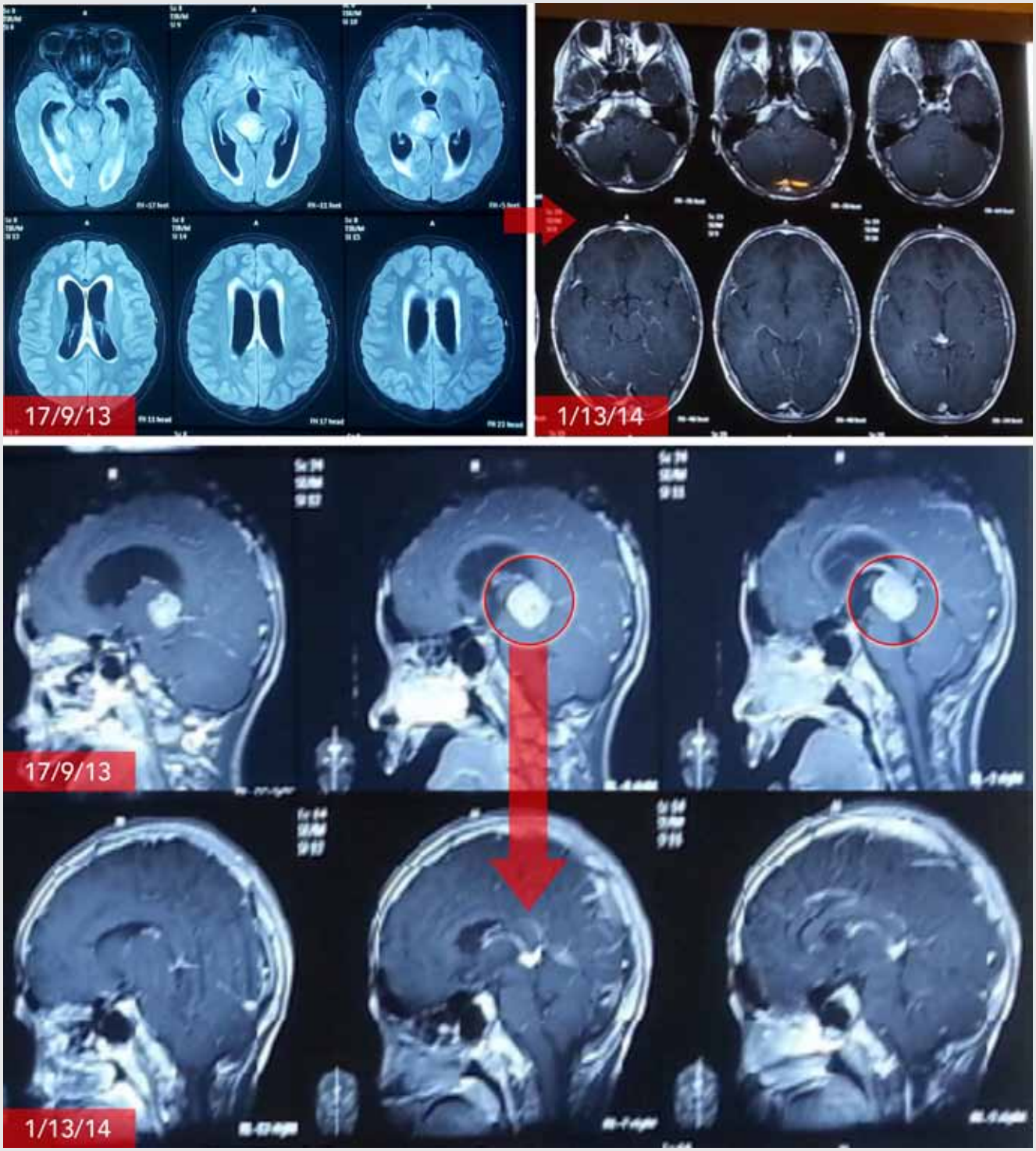

Figure C.1 Case Study: Boy (9 years old), Brain Cancer (High-Grade Pineal Parenchymal Tumor, WHO Grade 3): In this case the position of the tumor is linked directly to the forth ventricle through where the cerebro-spinal fluid discharged. Therefore, the dead cells resulted from ECCT treatment can be completely disposed, and all the tumor mass completely disappears as shown in the MRI images after 6 months of ECCT. The MRI results also shows diminishing hydrocephalus as the cancer gone.

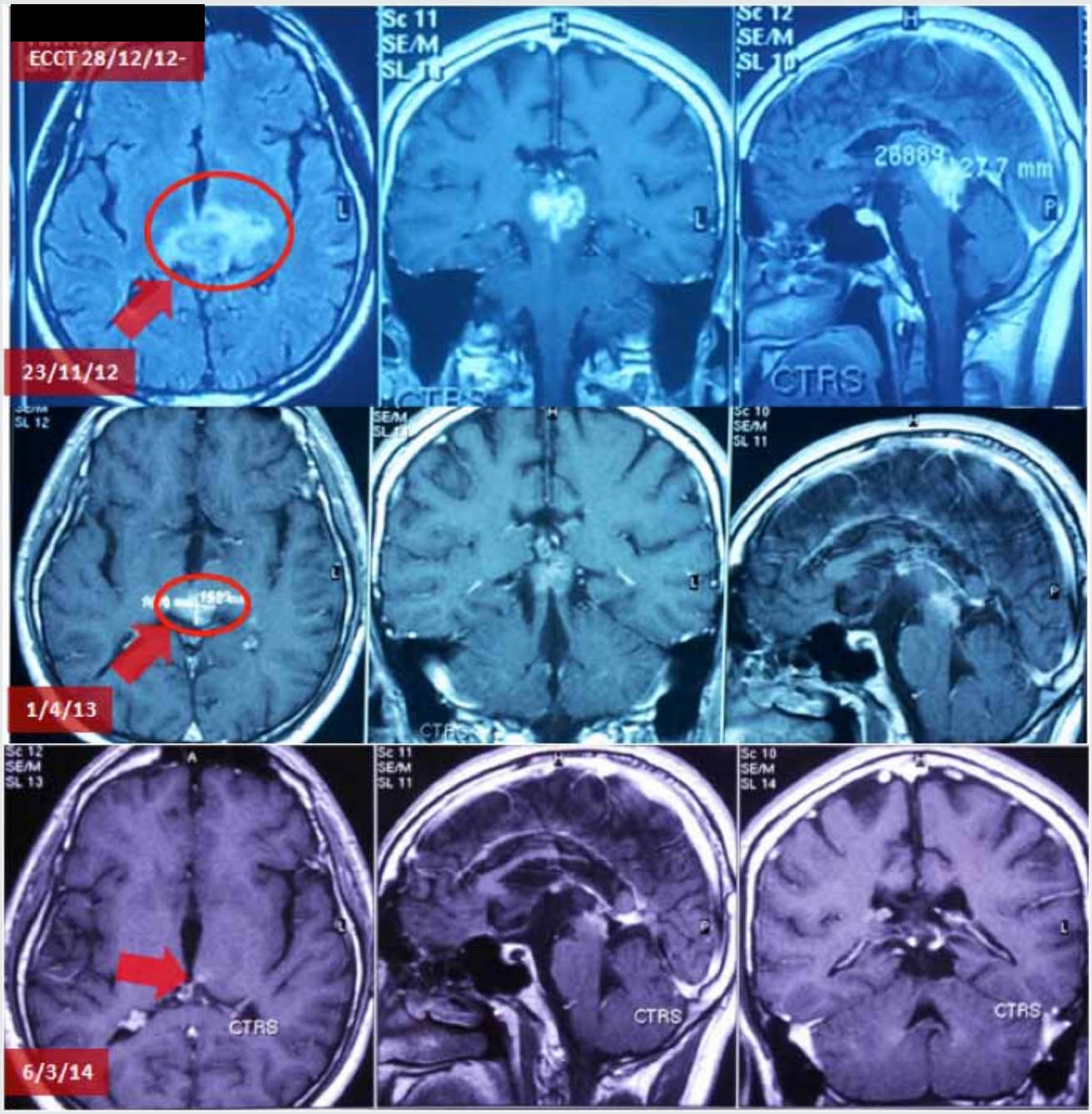

Figure C.2 Case Study: Male (22 years old) diagnosed with brain tumor at the pineal area extended to thalamus: The tumor mass is located at the mesenchepalon (pineal region) pressing to thalamus (MRI 23/11/12), causing impaired vision and severe headaches to the patients. After 4 months of ECCT treatment, the tumor size gradually decreases (04/01/13 MRI) and the patient continues to improve clinically. After 15 months of treatment, the tumor mass is almost undetectable by MRI (06/03/14) and the patient's condition almost recovered to normal. The tumor mass in this case is located in the area linked to the fourth ventricle through where the complete disposal of the resulted dead cells can occur. Using the ECCT the entire tumor in this case could be expected to disappear completely without surgery.

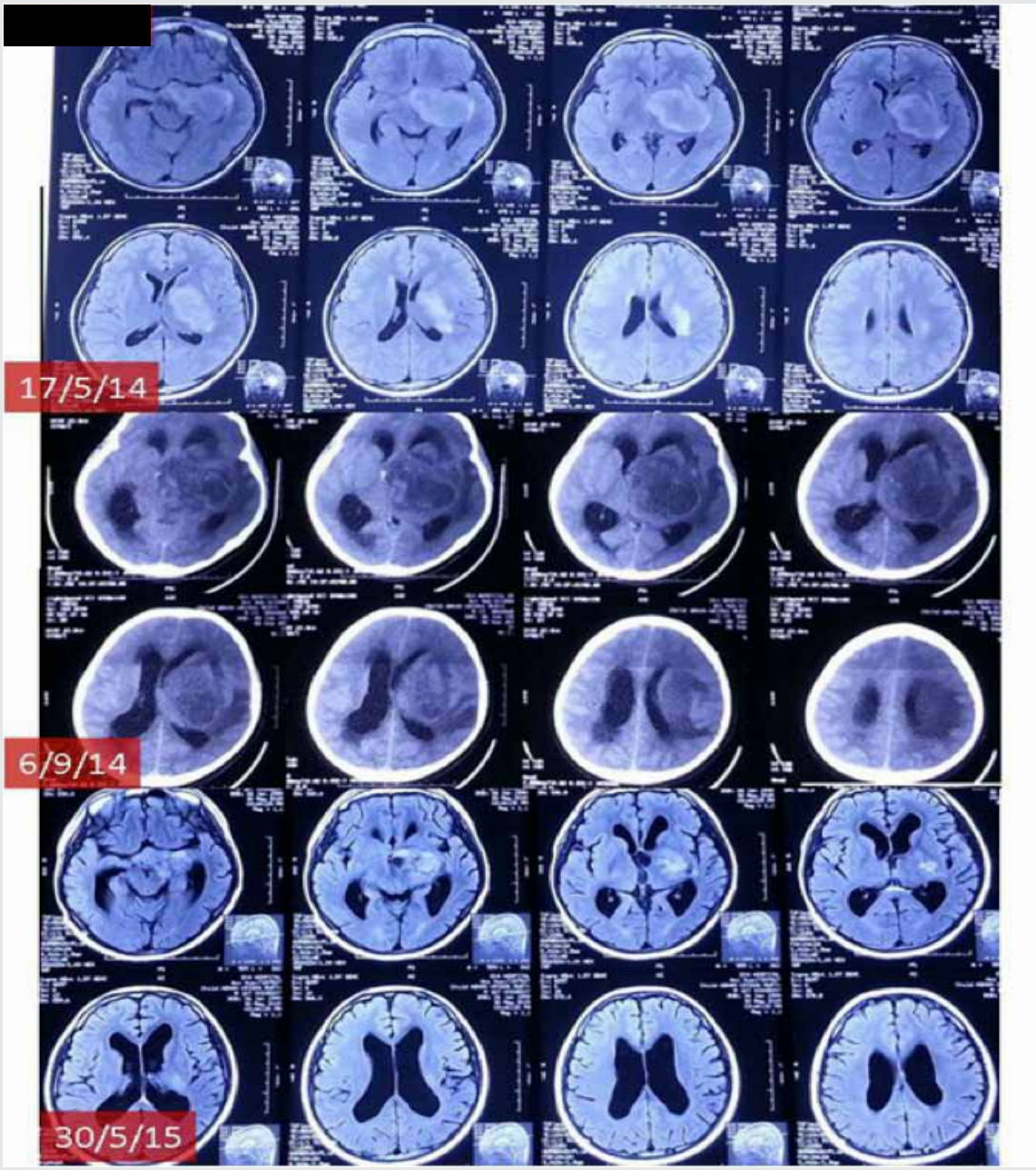

Figure C.3 Case Study: Boy (16 years old), diagoned with brain cancer (Pylocytic Astrocytoma) at the left basal ganglia: The tumor is located at the left basal ganglia with a midline shift to the right, pressing the mensencephalon (MRI 17/05/14), causing severe headache and problems in the right motoric function, vision and hearing. The patient's initial condition was very weak and paralyzed. After ECCT treatment for 4 months, it was found that the cancer worsened from the image of MRI (6/9/14), as well as the patient's general condition. The design of the ECCT apparel was then changed to more focusing on the deep side of the tumor. After 3 months of treatment with the new ECCT apparel design, the patient get significant improvement in the clinical conditions including motor, vision and hearing functions. 6 months after the usage of the new design, the MRI result (30/05/2015) shows significant reduction in the tumor size, the hydrocephalus has decreased, and the midline shift disappeared. In this case, proper design and usage of ECCT equipments link strongly to effective treatment of the brain cancer.

In Vitro and *in Vivo* Experiments

A series of in vitro experiments of culture cancer cells exposed to external electric wave using the technique have been conducted in University of Indonesia (Mursilatun, 2010; Sabrina, 2014) and University of Airlangga (Ajrina, 2013; Salim, 2015). The experiments used MCF—7 Human Breast Papilloma Cells as cancer cell sample and Fibroblast Vero Cells as normal cell sample. All in vitro experiments showed consistent results of significant reduction of the cancer cells, with no remarkable change identified in the control cells and normal cells. Figure D.1 shows the images of destructed cancer cells during exposure of the electric wave as compared to control cells. Figure D.2 shows the growth of cancer cells number as compared to normal cells during exposure of the electric wave. Animal testing have been conducted to normal as well as cancer implanted mice exposed to electric wave using the technique in National Institute of Health, Indonesia (2013) and Bogor Institute of Agriculture (2015). The animal testing showed no remarkable change physiologically and physically to normal mice, and significant shrinkage up to 40—90% in the size of the cancer for the mice implanted with breast cancer cells after 2 weeks of exposure with the electric wave, while no significant physiological side-effect identified.



Figure D.1 In vitro test with MCF-7 Human Breast Papilloma after 72 hours of exposure with electric wave (Sabrina, 2014)

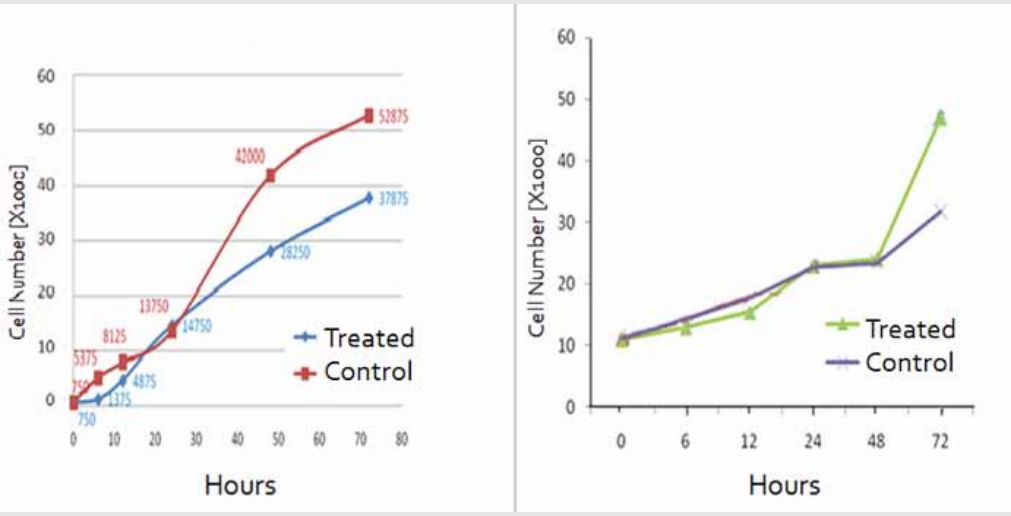

Figure D.2 In vitro test with MCF-7 Human Breast Papilloma (LEFT) as compared to normal Fibroblast Vero cells (RIGHT) after 72 hours of exposure with electric wave (Mursilatun, 2010).

Clinical Tests

A clinical test has been conducted to the first patient of 50 year old experienced stage 3—4 breast cancer after having total removal of the breast and the axillary nodes in early 2010, but the surgical margins were already infected with cancer cells. The patient refused to have chemo or radiation and after 6 months of surgery with already having recurrent on the after-surgery location she get informed to use the ECCT for the first time. After one month of treatment, the patient showed significant improvement clinically with all major complaints including pains gone and laboratory tests including blood, tumor markers, liver and kidney functions within normal ranges. After two months of treatment, echo scan and thoracic X-Ray showed no recurrent in the after-surgery breast nor metastasize on the lung. The first patient tested with the ECCT has now survived for more than 5 years since the first time diagnosed with the cancer in late 2009, in healthy condition with no essential complaint and all indicators including lung X-ray, abdominal and breast echo scans, laboratory tests including blood, liver and kidney functions within normal until now (as for June 2015).

A clinical test to the first brain cancer patient has been conducted to a patient of 21 years old experienced stage 3—4 brain astrocytoma on the left cerebellum after having surgery for VP shunt installation to treat the cerebro-spinal fluid. The patient refused to have radiation and were informed to use the ECCT for the first time for brain cancer case in 2011. The initial condition of the patient before treatment was in all parelyzed condition, unable to weak up from the bed. After one month of treatment, the patient showed significant improvement clinically. After 2 months of treatment the patient wa able to wake up from the bed, and walk slowly.The patient get complete recovery as normal after 3 months. How ever MRI scan still showed some infarcts on the location of original tumor. The patient has now (as for June 2015) survived for more than 4 years in prime condition as normal.

Clinical tests have also been conducted to 25 patients experienced breast cancers with staging of 2—3 in University of Indonesia (Handayani, 2012). All patients were informed to use the ECCT as primary treatment for their cancers. The study had been conducted for 6 months of treatment period, evaluating the effectiveness of the method based on the location of the tumors classified in five different quadrants of the breast, i.e. central, medial superior and inferior, and lateral inferior and superior regions. The results showed that the ECCT technique were the most effective in inhibiting cancer cell growth for breast cancers located in lateral superior quadrant, still showing inhibiting effect for breast cancers located in lateral inferior quadrant with less degree of effectiveness, while no significant effect for other locations of the tumor. The study reported that patients with significant inhibiting effects in their cancers indicated by significant shrinkage in the cancer sizes experienced significant changes on their body excretions including bad odor and excessive sweat and urine, and bad odor and dark to black colored feces, but no essential change reported in their physiological indicators. In contrast, patients with no significant change in the size of their tumors reported no significant change in their body excretions.

Subsequent clinical studies have also been conducted to the effectiveness of the method for treatments of breast cancers in University of Indonesia and Bandung Institute of Technology (Amdanita, 2013; Nurzannah, 2013; Nurhasanah, 2013), for treatments of brain, nasopharyngeal and lung cancers in University of Indonesia (Hendriyanto, 2013; Yulianto, 2012; Musthafa, 2012). All the studies showed that the responses of the cancer to the treatment of the ECCT strongly related to the design of electrode and the cancer cells pathology anatomy that correlated to electric properties. Statistical study have been conducted in University of Gadjah Mada to 76 patients with breast cancers, 23 patients with lung cancers, and 17 patients with brain cancers, all staged between 3—4, treated with the ECCT as primary treatment method between 2013—2014 (Dimyati dan Haryatmi, 2014). The study showed survival rates of 63% for breast cancer, 49% of brain cancer and 34% of lung cancer during the monitoring period of 1 year. Internal study to 4863 patients of breast cancers, 1098 patients of brain cancers, and 1189 patients of lung cancers, more than 70% of all patients staged 3—4, with treatment period of 0 to more than 3 years with the ECCT as the primary treatment method showed significant improvement in the survival rates of 80% for breast cancers, 75% for brain cancers, and 57% for lung cancers.

References:
Mursilatun, *Electric field effect on growth of cancer cells.* Bachelor of Thesis, 2010, Dept. of Medical Physics, University of Indonesia.

Sabrina, Qolby, *Effect of electric Field Treatment variation against Lethal level cell line MCF-7 (human Breast Cancer) in vitro and measurement of cell capacitance value.* Master Thesis, 2014, Dept. of Medical Physics, University of Indonesia.

Ajrina, Izzatun, *In vitro trial on antiproliferative and cytotoxic effect of 100 KHz Electric field towards MCF-7 Breast Cancer cells.* Bachelor Thesis, 2013, Dept. of Biology, University of Airlangga.

Salim, Sahudi, *The electro-static field effect on growth of Hella cell (Human Epithelial carcinoma cell line), an in vitro study.* Dissertation, 2015, School of Medicines, University of Airlangga.

Handayani, Yunita Kusuma, *The Effectiveness of Electro-Capacitive Cancer Therapy (ECCT) in Breast Cancer Treatment.* Bachelor Thesis, 2012, Dept. of Medical Physics, University of Indonesia.

Amdanita, Putri, *Evaluation of Capacitive Electrode Design to improve Effectiveness of Electro-Capacitive Cancer Therapy (ECCT) for Breast Cancer Treatment.* Bachelor Thesis, 2013, Dept. of Medical Physics, University of Indonesia.

Nurzannah, *Analysis of Electro Capacitive Cancer Treatment (ECCT) Efficiency in Breast Cancer Treatment Based on breast Anatomy.* Bachelor Thesis, 2013, Dept. of Medical Physics, University of Indonesia.

Nurhasanah, Siti, *Electrode design optimization for Electro-Capacitive Cancer Therapy (ECCT) in treatment of breast cancer.* Bachelor Thesis, 2013, Dept. of Biomedical Physics, Bandung Institute of Technology.

Hendriyanto, Markus, *Effectiveness of Electro-Capacitive Cancer Therapy (ECCT) for brain cancer treatment.* Bachelor Thesis, 2013, Dept. of Medical Physics, University of Indonesia.

Yulianto, Ahmad, *Electro-Capacitive Cancer Therapy (ECCT) design optimization for treatment of carcinoma Nasopharing.* Bachelor Thesis, 2012, Dept. of Medical Physics, University of Indonesia.

Dimyati, Hamid and Sri Haryatmi: "Weibull Regression model for testing factors Affecting survival of cancer therapy (ECCT)", *Proc. of ICAS 2014,* Khun Kuen, Thailand.

Taruno, Warsito P., Marlin R. Baidillah, Rommy I. Sulaiman, Ifnia Widora, Arbai Yusuf, Wahyu Widada, Muhammad S. Aljohani, Frans X. Suharyanto: "Comparission of Electrical Capacitive Volume Tomography and Ultrasonography for Breast Cancer Detection", *Advance Science, Engineering and Medicine,* Volume 6, 2014, pp.845-848 (4).

Acknowledgements:
Sincere appreciations and special thanks to all volunteer patients and their families that have contributed tremendously to the study and clinical tests.

Written and Edited by:
Dr. Warsito P. Taruno

Content Contributors:
Ahmad Novian Rahman Hakim, Almusfi Saputra, Al Amin Saichul Iman, Cepi Ridwan, Dessy Ariyanti, Dr. Firman Alamsyah, Habib Syeh Al Jufrie, Ikrimah, Marlin Ramadhan Baidillah, Nurul Firdausi Nuzulah, Panji Nursetia, Rommy Iman Sulaiman Rizki Edmi Edison, MD, PhD., Rohmadi, Sugiyanto, Wamid Antaboga.

Design:
Tubagus Moch Iqbal, Fauzan Zidni

Supervision:
Dr. Edi Sukur

Contact Us

Jl. Jalur Sutera, Kavling spectra - Blok 23 BC, no 10 - 12
Alam Sutera, Tangerang Indonesia 15325
☎ +62 21 293 15015 | 🖷 +62 21 293 14861
✉ info@c-techlabs.com

www.c-techlabs.com
edwartechnology
@edwartech